

Circulation

JOURNAL OF THE AMERICAN HEART ASSOCIATION



Aspirin Plus Clopidogrel Versus Aspirin Alone After Coronary Artery Bypass Grafting: The Clopidogrel After Surgery for Coronary Artery Disease (CASCADE) Trial

Alexander Kulik, Michel R. Le May, Pierre Voisine, Jean-Claude Tardif, Robert DeLarochelliere, Sarika Naidoo, George A. Wells, Thierry G. Mesana and Marc Ruel

Circulation published online Dec 6, 2010;

DOI: 10.1161/CIRCULATIONAHA.110.978007

Circulation is published by the American Heart Association, 7272 Greenville Avenue, Dallas, TX 75214

Copyright © 2010 American Heart Association. All rights reserved. Print ISSN: 0009-7322. Online ISSN: 1524-4539

The online version of this article, along with updated information and services, is located on the World Wide Web at:

<http://circ.ahajournals.org>

Subscriptions: Information about subscribing to *Circulation* is online at
<http://circ.ahajournals.org/subscriptions/>

Permissions: Permissions & Rights Desk, Lippincott Williams & Wilkins, a division of Wolters Kluwer Health, 351 West Camden Street, Baltimore, MD 21202-2436. Phone: 410-528-4050. Fax: 410-528-8550. E-mail:
journalpermissions@lww.com

Reprints: Information about reprints can be found online at
<http://www.lww.com/reprints>

Aspirin Plus Clopidogrel Versus Aspirin Alone After Coronary Artery Bypass Grafting The Clopidogrel After Surgery for Coronary Artery Disease (CASCADE) Trial

Alexander Kulik, MD, MPH; Michel R. Le May, MD; Pierre Voisine, MD; Jean-Claude Tardif, MD; Robert DeLarochelliere, MD; Sarika Naidoo, BSc; George A. Wells, PhD; Thierry G. Mesana, MD, PhD; Marc Ruel, MD, MPH

Background—Clopidogrel inhibits intimal hyperplasia in animal studies and therefore may reduce saphenous vein graft (SVG) intimal hyperplasia after coronary artery bypass grafting. The Clopidogrel After Surgery for Coronary Artery Disease (CASCADE) study was undertaken to evaluate whether the addition of clopidogrel to aspirin inhibits SVG disease after coronary artery bypass grafting, as assessed at 1 year by intravascular ultrasound.

Methods and Results—In this double-blind phase II trial, 113 patients undergoing coronary artery bypass grafting with SVGs were randomized to receive aspirin 162 mg plus clopidogrel 75 mg daily or aspirin 162 mg plus placebo daily for 1 year. The primary outcome was SVG intimal hyperplasia (mean intimal area) as determined by intravascular ultrasound at 1 year. Secondary outcomes were graft patency, major adverse cardiovascular events, and major bleeding. One-year intravascular ultrasound and coronary angiography were performed in 92 patients (81.4%). At 1 year, SVG intimal area did not differ significantly between the 2 groups (4.1 ± 2.0 versus 4.5 ± 2.1 mm², aspirin-clopidogrel versus aspirin-placebo, $P=0.44$). Overall 1-year graft patency was 95.2% in the aspirin-clopidogrel group compared with 95.5% in the aspirin-placebo group ($P=0.90$), and SVG patency was 94.3% in the aspirin-clopidogrel group versus 93.2% in the aspirin-placebo group ($P=0.69$). Freedom from major adverse cardiovascular events at 1 year was $92.9 \pm 3.4\%$ in the aspirin-clopidogrel group and $91.1 \pm 3.8\%$ in the aspirin-placebo group ($P=0.76$). The incidence of major bleeding at 1 year was similar for the 2 groups (1.8% versus 0%, aspirin-clopidogrel versus aspirin-placebo, $P=0.50$).

Conclusions—Compared with aspirin monotherapy, the combination of aspirin plus clopidogrel did not significantly reduce the process of SVG intimal hyperplasia 1 year after coronary artery bypass grafting.

Clinical Trial Registration—URL: <http://www.clinicaltrials.gov>. Unique identifier: NCT00228423.

(*Circulation*. 2010;122:2680-2687.)

Key Words: coronary artery bypass graft surgery ■ antiplatelet drugs ■ saphenous vein

Coronary artery bypass grafting (CABG) is an effective treatment for ischemic heart disease; however, the long-term results of CABG are compromised by the process of saphenous vein graft (SVG) disease.¹⁻³ In some series, up to 20% of SVGs occlude within the first year after bypass surgery.^{4,5} By 10 years after surgery, only 60% of SVGs are patent, and half of those that are patent have clinically important stenosis.^{1,2} As a result of graft and native vessel attrition, patients who have previously undergone CABG are at risk for subsequent ischemic events.^{1,2}

Clinical Perspective on p 2687

The process of SVG disease is composed of 3 interlinked stages: Thrombosis, intimal hyperplasia, and atherosclerosis.^{1,2} Early graft thrombosis can occur soon after CABG owing to focal endothelial disruption.² Grafts that survive this early period subsequently develop a platelet-mediated progressive thickening of the vessel wall termed intimal hyperplasia. Intimal hyperplasia involves smooth muscle cell proliferation and extracellular matrix protein synthesis, which forms a template for the devel-

Received July 13, 2010; accepted October 18, 2010.

From the Lynn Heart and Vascular Institute (A.K.), Boca Raton Regional Hospital, Boca Raton, Fla; the Divisions of Cardiac Surgery and Cardiology (A.K., M.R.L.M., S.N., T.G.M., M.R.), University of Ottawa Heart Institute, Ottawa, Ontario, Canada; the Departments of Cardiac Surgery and Cardiology (P.V., R.D.), Hôpital Laval, Quebec City, Quebec, Canada; the Department of Medicine (J.-C.T.), Montreal Heart Institute, Université de Montréal, Quebec, Canada; and the Department of Epidemiology and Community Medicine (G.A.W., M.R.), University of Ottawa, Ottawa, Ontario, Canada.

Correspondence to Marc Ruel, University of Ottawa Heart Institute, 40 Ruskin St, Suite 3403, Ottawa, Ontario, Canada K1Y 4W7. E-mail mruel@ottawaheart.ca

© 2010 American Heart Association, Inc.

Circulation is available at <http://circ.ahajournals.org>

DOI: 10.1161/CIRCULATIONAHA.110.978007

opment of atherosclerosis.^{2,6,7} Vein graft atherosclerosis generally develops 3 to 5 years after CABG, but atheromatous plaques have been identified as early as 1 year after surgery.² Therefore, the process of intimal hyperplasia, by its links to SVG narrowing, atherosclerosis, and eventual occlusion, may represent a novel target for the inhibition and prevention of SVG disease after CABG.

In cell culture experiments⁸ and in animal models of thrombosis,^{6,9,10} clopidogrel has been shown to inhibit the process of intimal proliferation and smooth muscle hyperplasia. Aspirin, on the other hand, does not inhibit intimal hyperplasia.^{6,11} To date, no clinical study has evaluated whether clopidogrel inhibits SVG intimal hyperplasia or improves angiographic graft patency after CABG.¹² In the Clopidogrel After Surgery for Coronary Artery Disease (CASCADE) study, we conducted a double-blind, placebo-controlled phase II clinical trial to evaluate whether the addition of clopidogrel to aspirin inhibits the development of SVG disease.³ Using intravascular ultrasound (IVUS), we assessed the process of SVG intimal hyperplasia 1 year after CABG. Secondary end points were angiographic graft patency, major adverse cardiovascular events, and safety outcomes.

Methods

Study Population

The CASCADE trial was conducted at the University of Ottawa Heart Institute, Ottawa, Canada, and at Hôpital Laval, Quebec City, Canada, from May 2006 to July 2009. Details of the study design and eligibility criteria have been published previously.³ Briefly, patients were eligible for study enrollment if they were scheduled to undergo first-time multivessel CABG with at least 2 SVGs, with or without the use of cardiopulmonary bypass. Patients were ineligible if they required valve surgery or long-term anticoagulation. Endoscopic SVG harvesting was not used in the study. Preoperative aspirin therapy was not withheld in the days that preceded surgery. The institutional review board of each participating surgical center approved the study protocol. Each patient provided written informed consent before enrollment.

Study Design

Postoperatively, patients were randomly assigned to receive either clopidogrel 75 mg or an identical-looking placebo once daily, starting on the day of surgery, for a duration of 1 year. All patients also received enteric coated aspirin 162 mg daily for the entire study period. Aspirin and the study medication were first administered when the postoperative chest tube drainage had decreased to less than 50 mL/h for 2 consecutive hours and was continued on a daily basis. A bolus of clopidogrel was not incorporated into the treatment protocol to minimize the risk of perioperative bleeding.

After hospital discharge, patients were followed up with clinic visits at 1, 6, and 12 months after surgery to document clinical events and ensure medication compliance. Home assessments were performed via telephone at 3 and 9 months. Patients were treated according to current guidelines,¹³ including the use of β -blockers and lipid-lowering therapy as tolerated. At 1 year, patients returned for a postoperative coronary angiogram and IVUS.

Randomization and Masking

Randomization was stratified according to the surgical center, the presence or absence of diabetes mellitus, and the use or nonuse of cardiopulmonary bypass during CABG. A block randomization schedule was generated by use of SAS 9.1 software (SAS, Cary, NC). Treatment assignment was coordinated by the hospital pharmacies, and all patients and study personnel were blinded to the treatment assignment. The extent of platelet inhibition was not assessed in the present study to avoid unmasking the patients' assigned treatment regimen.

Intravascular Ultrasonography

IVUS was used to assess the area of SVG intimal hyperplasia 1 year after surgery. Angiography was performed during the same session before IVUS to examine the native coronary arteries and the patency of all bypass grafts. A sequence randomization scheme was then used to determine which SVG would be evaluated by IVUS.³ The IVUS studies were performed with a 40-MHz imaging catheter (Atlantis SR Pro, Boston Scientific, Natick, Mass). The IVUS catheter was advanced into the graft, and study images were recorded with a validated motorized pullback device at 0.5 mm/s. Subsequently, using digitized images in a core laboratory, expert analysts blinded to the treatment assignment performed manual planimetric measurements of cross sections spaced at 1.0-mm intervals, in accordance with established standards.¹⁴ With the aorto-ostial anastomosis as a landmark, the most proximal 40 mm of the assigned SVG was analyzed. For each analyzed cross section, the lumen and external elastic lamina area were measured, and the area of intimal hyperplasia was determined (Figure 1). Mean intimal area per patient was calculated for the 40-mm analyzed segment.

Outcomes

The primary outcome of the study was mean SVG intimal area per patient. Secondary outcomes were angiographic SVG patency, major adverse cardiovascular events (cardiovascular death, myocardial infarction, cerebrovascular accident, hospitalization for coronary ischemia, and need for coronary intervention), and episodes of major and minor bleeding. Bleeding events were recorded according to the CURE (Clopidogrel in Unstable angina to prevent Recurrent Events) trial definitions.¹⁵ All end points were adjudicated in a blinded fashion.

Statistical Analysis

We compared follow-up measures and clinical outcomes on an intention-to-treat basis according to the randomization study group assignment. Vein graft intimal area was compared between the study groups by use of a 2-sided Student *t* test. Parametric continuous variables were compared with a 2-sided Student *t* test. Continuous data determined to be nonparametric (on the basis of the Shapiro-Wilk normality test) were compared between groups with a 2-sample Wilcoxon rank sum test. An ANCOVA was used to compare continuous variables after controlling for statistically significant covariates (ie, age). Categorical variables were compared with a Fisher's exact test. To account for the within-patient correlation, vein graft patency data were analyzed by logistic regression fit with generalized estimating equations methods. Time to major adverse cardiovascular event was determined for the study groups by the Kaplan-Meier method, and groups were compared with a log-rank test. A hazard ratio was calculated and is reported along with the 95% confidence interval. All reported probability values are 2-sided.

Further analyses were performed with the exclusion of off-pump patients, to account for patients who withdrew or prematurely discontinued the study drug during the trial ("on-protocol" analysis), and to adjust for randomization stratification factors (surgical center, the use of cardiopulmonary bypass, and the presence of diabetes mellitus). Lastly, additional sensitivity analysis was performed to account for missing data. If all SVGs were occluded at the time of the 1-year angiogram, then the mean value or 5 times the mean was imputed for the primary outcome (intimal area). Insertion of 5 times the mean led to skewing of the data, and therefore, the 2-sample Wilcoxon rank sum test was used for the latter analysis.

The sample size of the CASCADE trial was determined by use of intimal hyperplasia reference values reported in the literature. With IVUS, Hozumi et al¹⁶ determined that the mean intimal area of angiographically normal SVGs 1 year after CABG was 5.26 mm², with a standard deviation of 1.38 mm². Anticipating this degree of SVG intimal area at 1 year, 37 patients in each study group were required to detect a relative treatment difference of 20% in the primary outcome, at a power of 90% and 2-sided $\alpha=0.05$. Assuming a dropout rate of 35% or more, a total of 110 randomized patients were required.

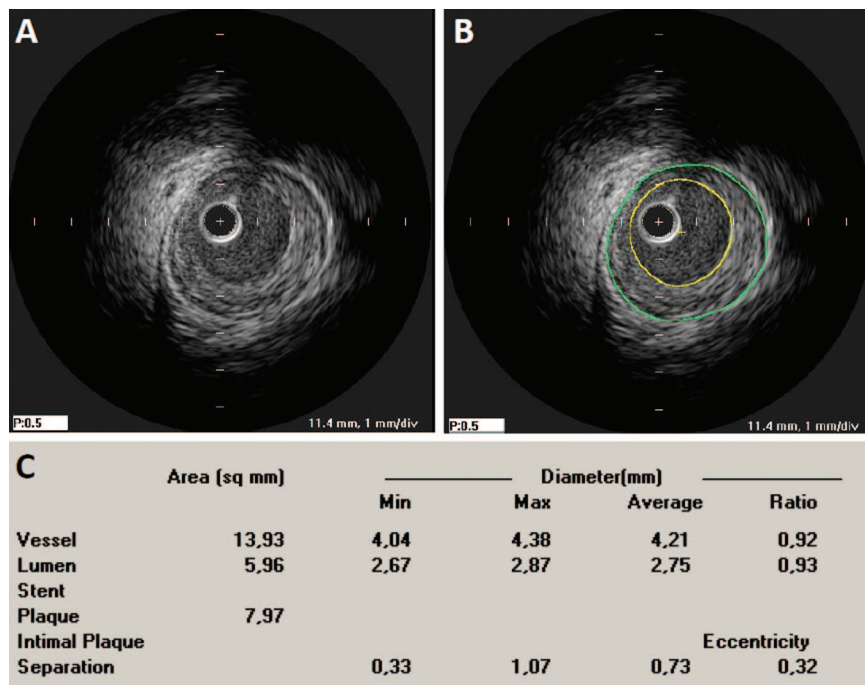


Figure 1. IVUS image of an SVG 1 year after coronary artery bypass graft surgery (A). Manual planimetric measurements (B) were performed to identify the vessel area (green outer outline, also known as the external elastic lamina area) and lumen area (yellow inner outline). Subtraction of the lumen area from the vessel area determines the plaque area, which represents vein graft intimal hyperplasia (C). Min indicates minimum; Max, maximum.

All authors had full access to the study data and take full responsibility for the integrity of the data and the accuracy of the data analysis. All authors have read and agree to the manuscript as written.

Results

Patients

From May 2006 to July 2008, 113 patients were randomly assigned to receive either aspirin plus clopidogrel (56 patients) or aspirin plus placebo (57 patients; Figure 2). The use of medications at baseline and demographic characteristics were similar in the 2 treatment groups, except for patient age (Table 1). Postoperatively, the use of medications did not differ between the 2 groups (Table 2). More than 90% of patients received statins and β -blockers after CABG.

IVUS and Angiography

One-year angiography was completed in 46 patients (82.1%) in the aspirin-clopidogrel group and in 46 patients (80.7%) in the aspirin-placebo group, with a total of 323 grafts examined. IVUS was performed in 90 (97.8%) of the 92 patients who underwent follow-up angiography. The 2 patients who had 1-year angiography but who did not concomitantly undergo IVUS presented the following issues: 1 patient (aspirin-placebo group) was found to have both SVGs occluded at the time of follow-up angiography, and the second patient (aspirin-placebo group) had 2 patent SVGs, but neither could be cannulated safely for the IVUS procedure because of technical factors.

As shown in Table 3, the primary outcome of the trial, SVG mean intimal area, did not differ significantly between the 2 groups (4.1 ± 2.0 versus 4.5 ± 2.1 mm², aspirin-clopidogrel versus aspirin-placebo, $P=0.44$). The addition of clopidogrel to aspirin led to a nonsignificant 7.6% relative reduction in SVG intimal area (absolute difference -0.3 mm², 95% confidence interval -1.2 to 0.5 mm²;

relative difference -7.6% , 95% confidence interval -26.9% to 11.7%).

Overall graft patency was 95.2% in the aspirin-clopidogrel group and 95.5% in the aspirin-placebo group ($P=0.90$). One-year internal thoracic artery graft patency was 96.6% in the aspirin-clopidogrel group and 100% in the aspirin-placebo group ($P=0.50$). One-year SVG patency was 94.3% in the aspirin-clopidogrel group compared with 93.2% in the aspirin-placebo group ($P=0.69$).

Clinical Outcomes

Table 4 summarizes the study clinical outcomes, adverse events, and reasons for study medication discontinuation. In the aspirin-clopidogrel group, 3 patients (5.3%) had a perioperative myocardial infarction; however, these patients all had patent grafts at 1-year angiography. One additional patient presented with a non-ST-elevation myocardial infarction 7 months after surgery. All grafts were patent at angiography, and percutaneous coronary intervention was performed for a new circumflex coronary artery lesion. In the aspirin-placebo group, 3 patients (5.3%) required hospitalization for coronary ischemia (1 myocardial infarction), including the aforementioned patient who had 2 occluded SVGs at the time of angiography. Stenting of 1 SVG and of the native left main coronary artery was performed in this patient. Two additional patients (3.5%) developed a cerebrovascular accident 5 days and 2 months after surgery, respectively, the latter of whom died of stroke complications 7 months later.

Overall, the frequency of major adverse cardiovascular events was not different between the 2 study groups. Freedom from major adverse cardiovascular events at 1 month and at 1 year was $94.6 \pm 3.0\%$ and $92.9 \pm 3.4\%$, respectively, in the aspirin-clopidogrel group, compared with $98.2 \pm 1.7\%$ and $91.1 \pm 3.8\%$, respectively, in the aspirin-placebo group (hazard ratio 0.8, 95% confidence interval 0.2 to 3.0, $P=0.76$).

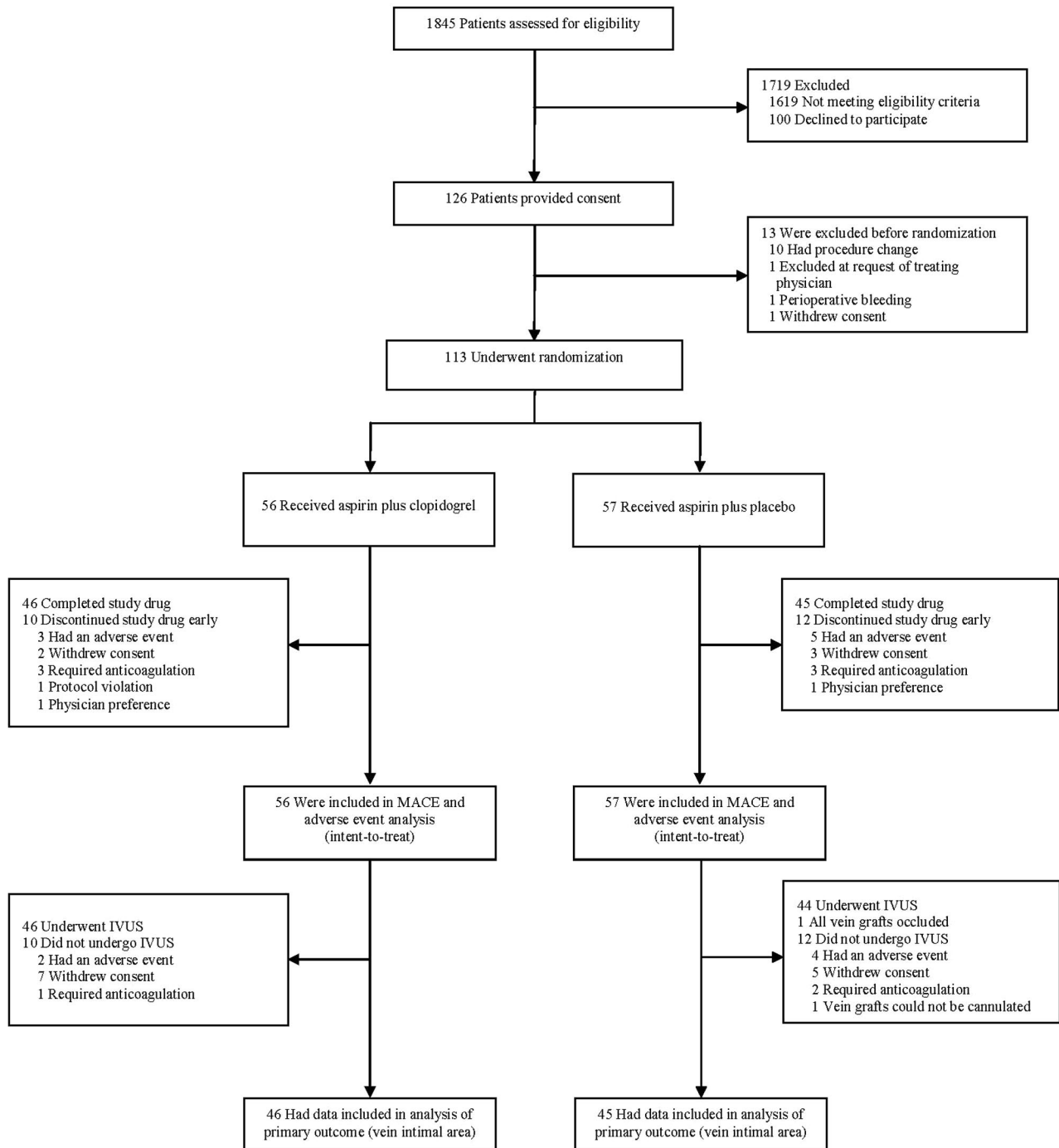


Figure 2. Study enrollment and follow-up. MACE indicates major adverse cardiovascular events.

The study drug was discontinued in 10 patients (17.9%) in the aspirin-clopidogrel group and in 12 patients (21.1%) in the aspirin-placebo group ($P=0.81$).

Perioperative Bleeding

In the early postoperative period, the amount of chest tube drainage after study drug administration was significantly greater in the aspirin-clopidogrel group (median 400 mL; first and third quartile 270 and 560 mL) than in the aspirin-placebo group (median 260 mL; first and third quartile 200 and 380 mL; $P=0.006$). However, there was no significant

difference in the amount of packed red blood cells required postoperatively between the aspirin-clopidogrel group (median 0 U; first and third quartile 0 and 0 U) and the aspirin-placebo group (median 0 U; first and third quartile 0 and 1 U; $P=0.57$). There was also no difference in the postoperative transfusion rate (23.2% versus 33.3%, aspirin-clopidogrel versus aspirin-placebo, $P=0.30$). One patient (1.8%) in the aspirin-clopidogrel group required reopening for bleeding in the early postoperative period. The reopening was performed before the administration of the study medication.

Table 1. Patient Characteristics

Characteristic	Aspirin-Clopidogrel (n=56)	Aspirin-Placebo (n=57)
Age, y	64.9±7.5	68.1±7.4
Male sex, %	91.1	87.7
Body mass index, kg/m ²	28.4±4.0	28.4±3.8
Diabetes mellitus, %	25.0	33.3
Current smoker, %	10.7	15.8
Hypertension, %	48.2	52.6
Hyperlipidemia, %	87.5	87.7
Acute coronary syndrome,* %	12.5	22.8
Heart failure, NYHA class 3–4, %	23.2	17.5
Preoperative creatinine, μmol/L	86.7±16.8	91.4±18.0
Preoperative medication use, %		
Aspirin	91.1	93.0
Clopidogrel	5.4	15.8
Statin	94.6	84.2
β-blocker	83.9	70.2
Angiotensin-converting enzyme inhibitor	53.6	47.4
Operative details		
No. of distal anastomoses	3.6±0.8	3.4±0.6
Left internal thoracic graft, %	100	98.2
Right internal thoracic graft, %	25.0	14.0
Cross-clamp time, min	66.2±22.4	62.9±17.7
Cardiopulmonary bypass time, min	91.5±28.1	88.7±20.9
Off-pump surgery, %	5.4	1.8

NYHA indicates New York Heart Association.

*Recent acute coronary syndrome within 1 month.

Late Bleeding Events

During follow-up, the incidence of major and minor bleeding events did not differ between the study groups. Major bleeding occurred in 1 patient (1.8%) in the aspirin-clopidogrel group compared with none in the aspirin-placebo group ($P=0.50$). Minor bleeding occurred in 3 patients (5.4%) in the aspirin-clopidogrel group and in 3 patients (5.3%) in the aspirin-placebo group ($P=1.0$).

Table 2. Postoperative Course

	Aspirin-Clopidogrel (n=56)	Aspirin-Placebo (n=57)	<i>P</i>
Mean length of stay			
Duration in intensive care, d	1.6±1.2	1.3±0.7	0.07
Duration in hospital, d	9.2±6.8	8.1±4.5	0.46
Medications at discharge, %			
Statin	91.1	91.2	1.00
β-blocker	94.6	91.2	0.72
Angiotensin-converting enzyme inhibitor	37.5	33.9	0.84

Table 3. Primary and Secondary Outcomes Evaluated at the 1-Year IVUS and Coronary Angiogram

	Aspirin-Clopidogrel	Aspirin-Placebo	<i>P</i>
IVUS	n=46	n=44	
Mean intimal area, mm ²	4.1±2.0	4.5±2.1	0.44
Coronary angiography, %	n=46	n=46	
Any graft occlusion	4.8	4.5	0.90
Vein graft occlusion	5.7	6.8	0.69
Internal thoracic artery occlusion	3.4	0	0.50
Vein graft stenosis	2.8	2.9	1.00
Patients with vein graft occlusion	13.0	13.0	1.00

IVUS indicates intravascular ultrasound.

Sensitivity Analysis

Adjustment for patient age in an ANCOVA did not reveal a significant association between clopidogrel and intimal area ($P=0.61$). Adjustment for stratification factors (surgical center, use of cardiopulmonary bypass, and the presence of diabetes) also did not lead to a significant association between clopidogrel and intimal area ($P=0.26$). Exclusion of

Table 4. Clinical Outcomes and Reasons for Study Drug Discontinuation

	Aspirin-Clopidogrel (n=56)	Aspirin-Placebo (n=57)	<i>P</i>
Death due to any cause	0 (0)	1 (1.8)*	1.00
Major adverse cardiovascular events			
Cardiovascular death	0 (0)	1 (1.8)	1.00
Myocardial infarction	4 (7.1)	1 (1.8)	0.21
Cerebrovascular accident	0 (0)	2 (3.5)	0.50
Hospitalization for coronary ischemia	1 (1.8)	3 (5.3)	0.62
Need for coronary intervention	1 (1.8)	2 (3.5)	1.00
Any adverse cardiovascular event	4 (7.1)†	5 (8.8)‡	1.00
Bleeding events			
Major bleeding	1 (1.8)	0 (0)	0.50
Minor bleeding	3 (5.4)	3 (5.3)	1.00
Study drug discontinuation	10 (17.9)	12 (21.1)	0.81
Reason for discontinuation			
Need for anticoagulation	3 (5.4)	3 (5.3)	
Adverse event	3 (5.4)	5 (8.8)	
Preference of patient	2 (3.6)	3 (5.3)	
Preference of physician (unblinding)	1 (1.8)	1 (1.8)	
Protocol violation	1 (1.8)	0 (0)	

Values are n (%).

*Cerebrovascular accident 2 months after surgery leading to death 7 months postoperatively.

†Includes 3 adverse cardiovascular events that occurred during the perioperative hospital stay.

‡Includes 1 adverse cardiovascular event that occurred during the perioperative hospital stay.

off-pump patients led to findings similar to the overall study results (mean intimal area 4.2 ± 2.2 versus 4.4 ± 2.1 mm², aspirin-clopidogrel versus aspirin-placebo, $P=0.59$). The on-protocol analysis also led to findings similar to the overall study results (mean intimal area 4.2 ± 2.2 versus 4.5 ± 2.4 mm², aspirin-clopidogrel versus aspirin-placebo, $P=0.52$). In the sensitivity analysis, imputation of the mean intimal area value for the patient who had 2 occluded SVGs did not lead to a significant difference between the 2 groups (mean intimal area 4.1 ± 2.0 versus 4.5 ± 2.1 mm², aspirin-clopidogrel versus aspirin-placebo, $P=0.44$). Imputation of 5 times the mean intimal area also did not lead to a significant difference between the 2 groups ($P=0.37$).

Discussion

CASCADE is the first randomized controlled trial to evaluate the impact of clopidogrel on the process of SVG disease after CABG using postoperative angiography and IVUS. We found that the addition of clopidogrel to aspirin did not lead to a significant reduction in intimal hyperplasia at 1 year compared with aspirin alone. Although CASCADE was not powered for angiographic or clinical outcomes, we also did not see a significant difference in SVG patency or cardiovascular events between the 2 treatment groups.

Vein graft intimal hyperplasia is a platelet-mediated process characterized by progressive wall thickening.^{2,6} Beginning within days after surgery, the proliferation of smooth muscle cells and the production of extracellular matrix proteins form a template for SVG atherosclerosis.^{2,7} Clopidogrel inhibits intimal proliferation and smooth muscle hyperplasia in cell culture experiments.⁸ In animal models of thrombosis, clopidogrel but not aspirin inhibits intimal proliferation and smooth muscle hyperplasia after arterial endothelial injury.^{6,9–11} Through the concurrent inhibition of both the thromboxane A₂ and ADP pathways, the combination of aspirin plus clopidogrel leads to an enhanced antithrombotic and antiproliferative effect.^{6,10} Despite these experimental findings, clopidogrel was not associated with a significant reduction in SVG intimal hyperplasia *in vivo*, as assessed in CASCADE 1 year after CABG. Whether clopidogrel prevents SVG atherosclerosis or improves late graft patency cannot be determined from the present study.

Previous randomized controlled trials have assessed dual-antiplatelet therapy with clopidogrel and aspirin for patients with cardiovascular disease. No clinical benefit was noted in 2 studies that evaluated combination antiplatelet therapy for patients with atherosclerotic risk factors and cerebrovascular, coronary, or peripheral vascular disease compared with aspirin alone.^{17,18} In contrast, the combination of clopidogrel and aspirin significantly improved outcomes compared with aspirin alone in patients undergoing percutaneous coronary intervention¹⁹ and in patients with acute coronary syndrome.^{15,20,21}

For patients undergoing CABG, current guidelines recommend aspirin monotherapy in doses of 75 to 162 mg daily starting within 48 hours of surgery²²; however, for patients who undergo urgent CABG after hospitalization with acute coronary syndrome, the guidelines recommend postoperative treatment with clopidogrel 75 mg daily for 9 to 12 months in addition to aspirin.²³ This suggestion has been based primar-

ily on data from the CURE trial, which demonstrated that dual-antiplatelet therapy was beneficial in reducing adverse outcomes in patients who presented with acute coronary syndromes and ultimately underwent CABG.¹⁵ Nevertheless, that benefit was entirely preoperative while patients were awaiting surgery, and no benefit for clopidogrel was demonstrated for CURE patients after CABG.²⁴

Clopidogrel is frequently prescribed by surgeons after CABG in the belief that it will prevent graft occlusion and possibly improve clinical outcomes.^{12,25} Although prospective randomized controlled trial data have been lacking in the field,¹² previous observational studies in the cardiac surgery literature have suggested that clopidogrel may improve postoperative outcomes.^{25–27} In a case series of off-pump CABG patients, Ibrahim et al²⁶ demonstrated that the addition of clopidogrel to aspirin was associated with a trend toward improved SVG patency 6 months after surgery. Similarly, in an observational study, Gurbuz et al²⁷ noted that postoperative clopidogrel was associated with less symptom recurrence and fewer adverse cardiac events. Moreover, post hoc subgroup analyses from multicenter randomized controlled studies have suggested a benefit associated with clopidogrel in patients with a history of CABG or in patients who underwent CABG after trial enrollment.^{24,28,29} Most recently, Gao et al³⁰ reported the results of a nonrandomized trial in which 197 patients were assigned to either clopidogrel 75 mg or clopidogrel 75 mg plus aspirin 100 mg daily after surgery on the basis of a weekly alternating-treatment scheme. Similar to the results of CASCADE, 1-year SVG patency did not differ between the 2 groups (93.5% versus 96.3% for clopidogrel alone versus clopidogrel plus aspirin, $P=0.25$) as assessed by computed tomography angiography.³⁰

The CASCADE study has limitations that should be taken into account when interpreting the results. The sample size of the trial was determined on the basis of the only available published values for SVG intimal hyperplasia at 1 year. Compared with the results of the small study by Hozumi et al¹⁶ (5.3 ± 1.4 mm²), we found lower values and greater variability for SVG intimal area at 1 year (4.3 ± 2.1 mm²). Dissimilar values for SVG intimal area at 1 year in the present study may be explained by our larger sample size, the different patient population, and the use of different IVUS equipment.

The results of CASCADE cannot conclusively exclude an inhibitory effect of clopidogrel on the development of SVG disease after CABG because the study may have been underpowered. Indeed, a nonsignificant 7.6% relative reduction in SVG intimal hyperplasia at 1 year was noted with the addition of clopidogrel to aspirin. This could represent a potential signal of physiological benefit, and we estimated, on the basis of these data, that 450 patients in each study arm would have been required to achieve statistical significance ($P < 0.05$, power 90%). Newer antiplatelet agents such as prasugrel³¹ or ticagrelor³² may prove to be more effective at inhibiting SVG graft intimal hyperplasia by providing more consistent inhibition of the P2Y₁₂ receptor. To this end, CASCADE provides data pertaining to SVG intimal hyperplasia at 1 year that are current and based on a greater number of subjects than previously available. These data may be of

use for the design of future IVUS trials to evaluate the pharmacological inhibition of SVG disease after CABG.

Complete angiographic follow-up was not achieved in the CASCADE study; however, the angiography rate of 81% compares favorably with recently published post-CABG trials that reported rates of 76% to 78% 1 year after surgery.^{4,5} Although no angiographic or clinical benefit was associated with the use of clopidogrel in CASCADE, outcome differences were not anticipated because the study was powered to detect a difference in the process of SVG intimal hyperplasia. As is evident in Figure 2, a number of patients who were evaluated for enrollment in CASCADE did not meet the study eligibility criteria. This mainly relates to the frequent use of arterial conduits during CABG at the 2 participating centers, with relatively few patients meeting the inclusion criteria that mandated the use of at least 2 SVGs. Finally, endoscopic SVG harvesting was not used in the CASCADE study, although it is commonly used at other centers. The subject of controversy, the use of endoscopic harvesting has been reported to adversely impact SVG patency.³³

In summary, the CASCADE trial indicated that compared with aspirin monotherapy, the combination of aspirin plus clopidogrel did not significantly reduce SVG intimal hyperplasia 1 year after CABG. A larger trial with clopidogrel or newer antiplatelet agents with purported advantages over clopidogrel may constitute important areas for future research targeting the inhibition of SVG disease after CABG.

Sources of Funding

The CASCADE trial was funded by research grants from the Physicians' Services Incorporated Foundation, Boston Scientific Inc, and the Bristol-Myers Squibb Sanofi Canada Partnership. Boston Scientific supplied the IVUS catheters used during the course of this study. The Bristol-Myers Squibb Sanofi Canada Partnership provided the study medication (clopidogrel and matching placebo) and financial support for the trial. The study authors alone designed the trial, analyzed and interpreted the data, wrote the manuscript, and decided to submit the paper for publication. The authors attest to the completeness and accuracy of the data gathering and analysis.

Disclosures

Drs Ruel and Le May received research support from the Bristol-Myers Squibb Sanofi Canada Partnership for the conduct of the CASCADE trial. The remaining authors report no conflicts.

References

- Fitzgibbon GM, Kafka HP, Leach AJ, Keon WJ, Hooper GD, Burton JR. Coronary bypass graft fate and patient outcome: angiographic follow-up of 5,065 grafts related to survival and reoperation in 1,388 patients during 25 years. *J Am Coll Cardiol*. 1996;28:616–626.
- Motwani JG, Topol EJ. Aortocoronary saphenous vein graft disease: pathogenesis, predisposition, and prevention. *Circulation*. 1998;97:916–931.
- Kulik A, Le May M, Wells GA, Mesana TG, Ruel M. The Clopidogrel After Surgery for Coronary Artery Disease (CASCADE) randomized controlled trial: clopidogrel and aspirin versus aspirin alone after coronary bypass surgery [NCT00228423]. *Curr Control Trials Cardiovasc Med*. 2005;6:15.
- Desai ND, Cohen EA, Naylor CD, Fremes SE. A randomized comparison of radial-artery and saphenous-vein coronary bypass grafts. *N Engl J Med*. 2004;351:2302–2309.
- Alexander JH, Hafley G, Harrington RA, Peterson ED, Ferguson TB Jr, Lorenz TJ, Goyal A, Gibson M, Mack MJ, Gennevois D, Califf RM, Kouchoukos NT. Efficacy and safety of edifoligide, an E2F transcription factor decoy, for prevention of vein graft failure following coronary artery bypass graft surgery: PREVENT IV: a randomized controlled trial. *JAMA*. 2005;294:2446–2454.
- Herbert JM, Dol F, Bernat A, Falotico R, Lale A, Savi P. The antiaggregating and antithrombotic activity of clopidogrel is potentiated by aspirin in several experimental models in the rabbit. *Thromb Haemost*. 1998;80:512–518.
- Fingerle J, Johnson R, Clowes AW, Majesky MW, Reidy MA. Role of platelets in smooth muscle cell proliferation and migration after vascular injury in rat carotid artery. *Proc Natl Acad Sci U S A*. 1989;86:8412–8416.
- Hermann A, Weber AA, Schror K. Clopidogrel inhibits platelet adhesion and platelet-dependent mitogenesis in vascular smooth muscle cells. *Thromb Res*. 2002;105:173–175.
- Herbert JM, Tissinier A, Defreyne G, Maffrand JP. Inhibitory effect of clopidogrel on platelet adhesion and intimal proliferation after arterial injury in rabbits. *Arterioscler Thromb*. 1993;13:1171–1179.
- Harker LA, Marzec UM, Kelly AB, Chronos NR, Sundell IB, Hanson SR, Herbert JM. Clopidogrel inhibition of stent, graft, and vascular thrombogenesis with antithrombotic enhancement by aspirin in nonhuman primates. *Circulation*. 1998;98:2461–2469.
- Clowes AW, Karnovsky MJ. Failure of certain antiplatelet drugs to affect myointimal thickening following arterial endothelial injury in the rat. *Lab Invest*. 1977;36:452–464.
- Kulik A, Chan V, Ruel M. Antiplatelet therapy and coronary artery bypass graft surgery: perioperative safety and efficacy. *Expert Opin Drug Saf*. 2009;8:169–182.
- Eagle KA, Guyton RA, Davidoff R, Edwards FH, Ewy GA, Gardner TJ, Hart JC, Herrmann HC, Hillis LD, Hutter AM Jr, Lytle BW, Marlow RA, Nugent WC, Orszulak TA. ACC/AHA 2004 guideline update for coronary artery bypass graft surgery: a report of the American College of Cardiology/American Heart Association Task Force on Practice Guidelines (Committee to Update the 1999 Guidelines for Coronary Artery Bypass Graft Surgery). *Circulation*. 2004;110:e340–e437.
- Mintz GS, Nissen SE, Anderson WD, Bailey SR, Erbel R, Fitzgerald PJ, Pinto FJ, Rosenfield K, Siegel RJ, Tuzcu EM, Yock PG; American College of Cardiology Clinical Expert Consensus Document on Standards for Acquisition, Measurement and Reporting of Intravascular Ultrasound Studies (IVUS). A report of the American College of Cardiology Task Force on Clinical Expert Consensus Documents. *J Am Coll Cardiol*. 2001;37:1478–1492.
- Yusuf S, Zhao F, Mehta SR, Chrolavicius S, Tognoni G, Fox KK. Effects of clopidogrel in addition to aspirin in patients with acute coronary syndromes without ST-segment elevation. *N Engl J Med*. 2001;345:494–502.
- Hozumi T, Yoshikawa J, Yoshida K, Akasaka T, Takagi T, Honda Y, Okura H. Use of intravascular ultrasound for in vivo assessment of changes in intimal thickness of angiographically normal saphenous vein grafts one year after aortocoronary bypass surgery. *Heart*. 1996;76:317–320.
- Diener HC, Bogousslavsky J, Brass LM, Cimminiello C, Csiba L, Kaste M, Leys D, Matias-Guiu J, Rupprecht HJ. Aspirin and clopidogrel compared with clopidogrel alone after recent ischaemic stroke or transient ischaemic attack in high-risk patients (MATCH): randomised, double-blind, placebo-controlled trial. *Lancet*. 2004;364:331–337.
- Bhatt DL, Fox KA, Hacke W, Berger PB, Black HR, Boden WE, Cacoub P, Cohen EA, Creager MA, Easton JD, Flather MD, Haffner SM, Hamm CW, Hankey GJ, Johnston SC, Mak KH, Mas JL, Montalescot G, Pearson TA, Steg PG, Steinhilb SR, Weber MA, Brennan DM, Fabry-Ribaud L, Booth J, Topol EJ. Clopidogrel and aspirin versus aspirin alone for the prevention of atherothrombotic events. *N Engl J Med*. 2006;354:1706–1717.
- Steinhilb SR, Berger PB, Mann JT III, Fry ET, DeLago A, Wilmer C, Topol EJ. Early and sustained dual oral antiplatelet therapy following percutaneous coronary intervention: a randomized controlled trial. *JAMA*. 2002;288:2411–2420.
- Chen ZM, Jiang LX, Chen YP, Xie JX, Pan HC, Peto R, Collins R, Liu LS. Addition of clopidogrel to aspirin in 45,852 patients with acute myocardial infarction: randomised placebo-controlled trial. *Lancet*. 2005;366:1607–1621.
- Sabatine MS, Cannon CP, Gibson CM, Lopez-Sendon JL, Montalescot G, Theroux P, Claeys MJ, Cools F, Hill KA, Skene AM, McCabe CH, Braunwald E. Addition of clopidogrel to aspirin and fibrinolytic therapy for myocardial infarction with ST-segment elevation. *N Engl J Med*. 2005;352:1179–1189.
- Smith SC Jr, Allen J, Blair SN, Bonow RO, Brass LM, Fonarow GC, Grundy SM, Hiratzka L, Jones D, Krumholz HM, Mosca L, Pasternak

- RC, Pearson T, Pfeffer MA, Taubert KA. AHA/ACC guidelines for secondary prevention for patients with coronary and other atherosclerotic vascular disease: 2006 update: endorsed by the National Heart, Lung, and Blood Institute. *Circulation*. 2006;113:2363–2372.
23. Anderson JL, Adams CD, Antman EM, Bridges CR, Califf RM, Casey DE Jr, Chavey WE II, Fesmire FM, Hochman JS, Levin TN, Lincoff AM, Peterson ED, Theroux P, Wenger NK, Wright RS, Smith SC Jr, Jacobs AK, Halperin JL, Hunt SA, Krumholz HM, Kushner FG, Lytle BW, Nishimura R, Ornato JP, Page RL, Riegel B. ACC/AHA 2007 guidelines for the management of patients with unstable angina/non–ST-elevation myocardial infarction: a report of the American College of Cardiology/American Heart Association Task Force on Practice Guidelines (Writing Committee to Revise the 2002 Guidelines for the Management of Patients With Unstable Angina/Non–ST-Elevation Myocardial Infarction): developed in collaboration with the American College of Emergency Physicians, the Society for Cardiovascular Angiography and Interventions, and the Society of Thoracic Surgeons: endorsed by the American Association of Cardiovascular and Pulmonary Rehabilitation and the Society for Academic Emergency Medicine. *Circulation*. 2007;116:e148–e304.
 24. Fox KA, Mehta SR, Peters R, Zhao F, Lakkis N, Gersh BJ, Yusuf S. Benefits and risks of the combination of clopidogrel and aspirin in patients undergoing surgical revascularization for non–ST-elevation acute coronary syndrome: the Clopidogrel in Unstable angina to prevent Recurrent ischemic Events (CURE) Trial. *Circulation*. 2004;110:1202–1208.
 25. Kim DH, Daskalakis C, Silvestry SC, Sheth MP, Lee AN, Adams S, Hohmann S, Medvedev S, Whellan DJ. Aspirin and clopidogrel use in the early postoperative period following on-pump and off-pump coronary artery bypass grafting. *J Thorac Cardiovasc Surg*. 2009;138:1377–1384.
 26. Ibrahim K, Tjomsland O, Halvorsen D, Wiseth R, Wahba A, Karevold A, Haaverstad R. Effect of clopidogrel on midterm graft patency following off-pump coronary revascularization surgery. *Heart Surg Forum*. 2006;9:E581–E586.
 27. Gurbuz AT, Zia AA, Vuran AC, Cui H, Aytac A. Postoperative clopidogrel improves mid-term outcome after off-pump coronary artery bypass graft surgery: a prospective study. *Eur J Cardiothorac Surg*. 2006;29:190–195.
 28. Bhatt DL, Chew DP, Hirsch AT, Ringleb PA, Hacke W, Topol EJ. Superiority of clopidogrel versus aspirin in patients with prior cardiac surgery. *Circulation*. 2001;103:363–368.
 29. Hirsh J, Bhatt DL. Comparative benefits of clopidogrel and aspirin in high-risk patient populations: lessons from the CAPRIE and CURE studies. *Arch Intern Med*. 2004;164:2106–2110.
 30. Gao C, Ren C, Li D, Li L. Clopidogrel and aspirin versus clopidogrel alone on graft patency after coronary artery bypass grafting. *Ann Thorac Surg*. 2009;88:59–62.
 31. Wiviott SD, Braunwald E, McCabe CH, Montalescot G, Ruzyllo W, Gottlieb S, Neumann FJ, Ardissino D, De Servi S, Murphy SA, Riesmeyer J, Weerakkody G, Gibson CM, Antman EM. Prasugrel versus clopidogrel in patients with acute coronary syndromes. *N Engl J Med*. 2007;357:2001–2015.
 32. Wallentin L, Becker RC, Budaj A, Cannon CP, Emanuelsson H, Held C, Horrow J, Husted S, James S, Katus H, Mahaffey KW, Scirica BM, Skene A, Steg PG, Storey RF, Harrington RA, Freij A, Thorsen M. Ticagrelor versus clopidogrel in patients with acute coronary syndromes. *N Engl J Med*. 2009;361:1045–1057.
 33. Lopes RD, Hafley GE, Allen KB, Ferguson TB, Peterson ED, Harrington RA, Mehta RH, Gibson CM, Mack MJ, Kouchoukos NT, Califf RM, Alexander JH. Endoscopic versus open vein-graft harvesting in coronary-artery bypass surgery. *N Engl J Med*. 2009;361:235–244.

CLINICAL PERSPECTIVE

Coronary artery bypass grafting (CABG) is an effective treatment for ischemic heart disease, but its long-term results are compromised by the development of saphenous vein graft (SVG) disease. After surgery, a platelet-mediated thickening of the SVG wall occurs, with smooth muscle cell proliferation and extracellular matrix protein synthesis. This process, termed intimal hyperplasia, forms a template for the development of SVG atherosclerosis and eventual occlusion. Clopidogrel has been shown to inhibit intimal hyperplasia in animal studies and therefore may reduce SVG intimal hyperplasia after coronary artery bypass grafting. In the Clopidogrel After Surgery for Coronary Artery Disease (CASCADE) study, we conducted a double-blind, placebo-controlled trial to evaluate whether the addition of clopidogrel to aspirin inhibits the development of SVG disease. A total of 113 patients undergoing coronary artery bypass grafting with SVGs were randomized to receive either aspirin 162 mg plus clopidogrel 75 mg daily or aspirin 162 mg plus placebo daily for 1 year, followed by SVG intravascular ultrasound and coronary angiography. The primary outcome, SVG intimal area at 1 year, did not differ significantly between the 2 groups (4.1 ± 2.0 versus 4.5 ± 2.1 mm², aspirin-clopidogrel versus aspirin-placebo, $P=0.44$). Graft patency and freedom from major adverse cardiovascular events also did not significantly differ between the 2 groups. In summary, CASCADE indicated that compared with aspirin monotherapy, the combination of aspirin plus clopidogrel did not significantly reduce SVG intimal hyperplasia 1 year after coronary artery bypass grafting. Newer antiplatelet agents with purported advantages over clopidogrel may constitute important areas for future research to target the inhibition of SVG disease after CABG.